

Mycoplasma pneumoniae-associated vasoplegic shock and perimyocarditis in an adolescent

Submission ID: 1259677

Program: Section on Critical Care

Submission Type: Case Report

Authors:

Manish Kumar, MD
Pediatrics Resident
Carilion Roanoke Memorial Hospital, Roanoke, VA, USA

Virginia A. Powel, MD, MPH, Fellow of AAP, member of SOCC
Medical Director and Section Chief
Carilion Pediatrics Critical Care, Roanoke, VA, USA

Introduction

Mycoplasma pneumoniae (MP) is the smallest bacterial pathogen that causes pulmonary and extrapulmonary diseases of varying severity. Although cardiovascular complications of MP are uncommon, they can be life-threatening. We describe a patient who presented with vasoplegic shock prior to evolving into perimyocarditis, which is a novel presentation of this organism.

Case Description

A previously healthy 17-year-old young man who presented to an outside facility with a 4-day-history of high-grade fever, myalgia, loose stools, and headache. He developed an erythematous maculopapular rash with target lesions consistent with erythema multiforme. Inflammatory markers were elevated and cerebrospinal fluid was normal. Ceftriaxone and vancomycin were started outside, and doxycycline was added upon admission. However, within few hours, he developed fluid-refractory distributive shock that subsequently evolved into cardiogenic shock. Troponin and pro-B-type-natriuretic-peptide levels were significantly elevated. An echocardiogram demonstrated systolic dysfunction and a small pericardial effusion. He required norepinephrine, epinephrine, and milrinone infusions, controlled diuresis, and positive pressure support with BiPAP followed by intubation and ventilation, as well as steroid and intravenous immunoglobulin. He achieved hemodynamic stability and troponin/BNP started to improve although he developed cardiac arrhythmias including atrial fibrillation that responded to amiodarone infusion. A cardiac MRI demonstrated extensive biventricular myocarditis and a moderate pericardial effusion. He had an extensive work-up that revealed significantly elevated titers of MP-IgM. He completed a 14-day-course of doxycycline, and was discharged home on low-dose-aspirin and metoprolol. He was asymptomatic upon follow-up, and his echocardiogram showed normal ventricular function and resolution of pericardial effusion.

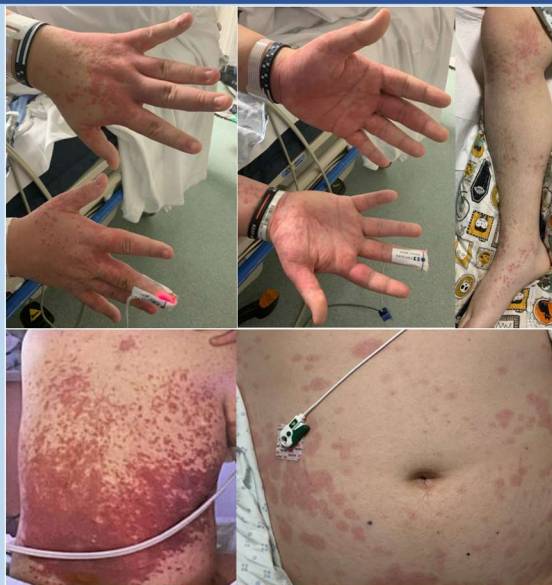

Figure 1: Rash involving hands, including palms, legs, back, and abdomen demonstrating targetoid lesions

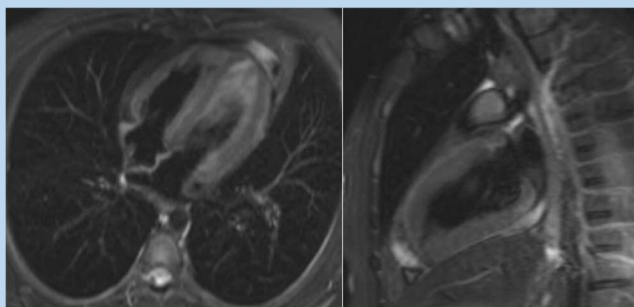


Figure 2: Cardiac MRI demonstrating evidence of biventricular myocarditis and pericardial effusion

Discussion

Cardiovascular involvement is an uncommon but severe complication of MP. Our patient had an unusual presentation with development of vasoplegic shock followed by evidence of perimyocarditis which has not been described earlier. The pathogenesis of MP-associated -carditis involves three mechanisms including direct invasion of MP into the heart via lymphatic vessels or circulatory system, autoimmune mechanism via a cross-reaction between the MP lipid antigen and cardiac tissue, and formation of microthrombi in the coronary arteries.

The treatment includes symptomatic therapy and antibiotic (macrolide, tetracycline, or fluoroquinolone). The prevalence of macrolide-resistant MP (MRMP) in the area should be considered while selecting the antibiotic. For severe presentations of MP infection, additional treatment with IVIG, corticosteroid, or plasmapheresis may be beneficial.

Conclusion

Cardiovascular complications caused by MP are uncommon, and although MP-induced perimyocarditis is known, presentation with vasoplegic shock may pose challenges to management. Aggressive treatment with appropriate vasoactive and inotropic medications, judicious use of IVIG and/or corticosteroid, along with appropriate antibiotic use while keeping MRMP in mind, are key to improved outcome of this potentially life-threatening condition.

References

- Bajantri B, Venkatram S, Diaz-Fuentes G. *Mycoplasma pneumoniae*: a potentially severe infection. *J Clin Med Res* 2018;10:535-544.
- Narita M. Pathogenesis of extrapulmonary manifestations of *Mycoplasma pneumoniae* infection with special reference to pneumonia. *J Infect Chemother* 2010;16:162–169.
- Ior-Robinson D. Immunopathological aspects of *Mycoplasma pneumoniae* infection. *Current Pediatric Reviews*. 2013;9(4):273-278.
- Okada T, Morozumi M, Tajima T, Hasegawa M, Sakata H, Ohnari S, et al. Rapid effectiveness of minocycline or doxycycline against macrolide-resistant *Mycoplasma pneumoniae* infection in a 2011 outbreak among Japanese children. *Clin Infect Dis* 2012;55:1642-1649.
- Waites K. Antimicrobial susceptibilities and treatment options for pediatric *Mycoplasma pneumoniae* infections - does macrolide resistance matter? *Current Pediatric Reviews*. 2013;9(4):279–288.

Disclosure: Authors have no financial relationships to disclose